

## Femoroacetabular impingement (FAI)

### What is femoroacetabular impingement?

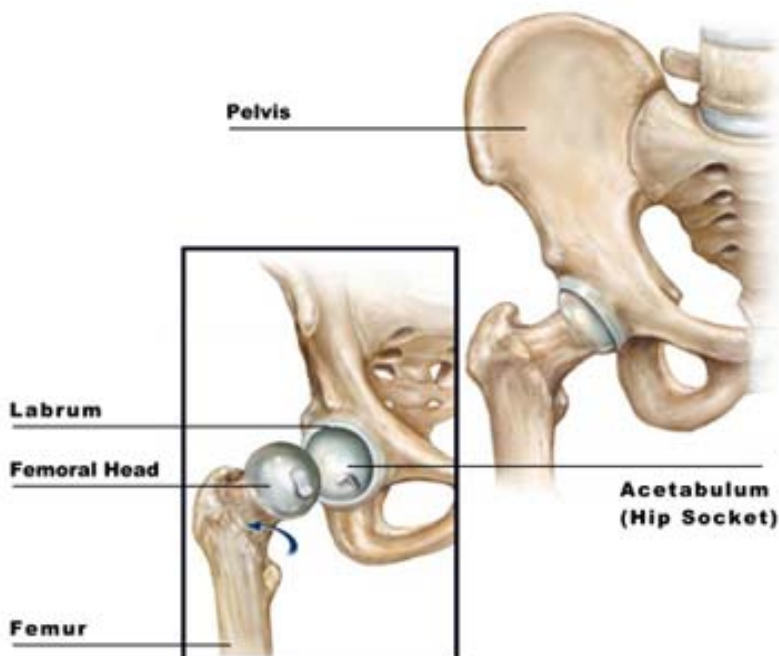
Femoroacetabular impingement (FAI) is a condition in which there is abnormal contact (impingement) between the rim of the acetabulum (hip joint socket) and femoral head-neck junction (the bone just below the ball part of the thigh bone), on movement of the hip.

The most common movement that brings on pain is hip flexion (knee towards chest).

Patients will experience pain, usually in the groin, but sometimes further down the front of the thigh, side or back of the hip. There may be episodes of clicking in the hip, or the sensation that it is coming out of joint.

Certain activities, particularly those which involve hip flexion (e.g. football, dancing, ballet, and aerobics) will make the pain worse. Patients often find that sitting for a prolonged period of time, e.g. a long car journey, will bring on groin pain and they often struggle to move into a more comfortable position.

### Diagram of the hip joint

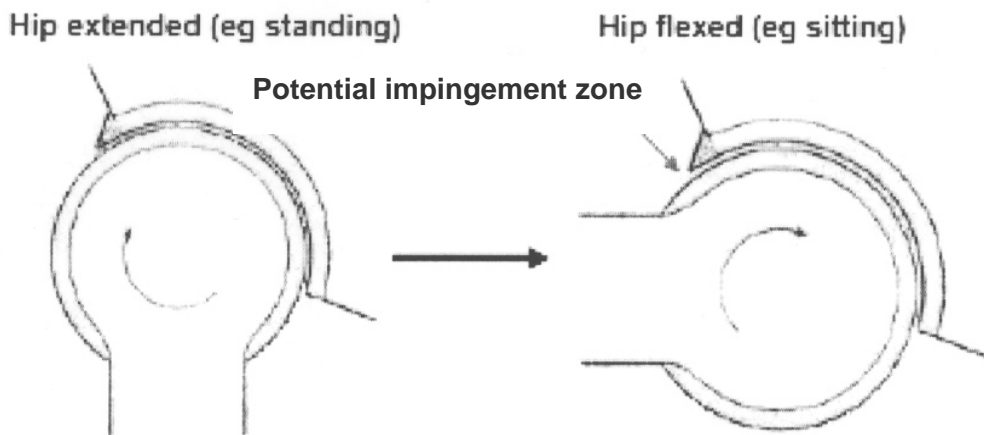


## How does FAI occur?

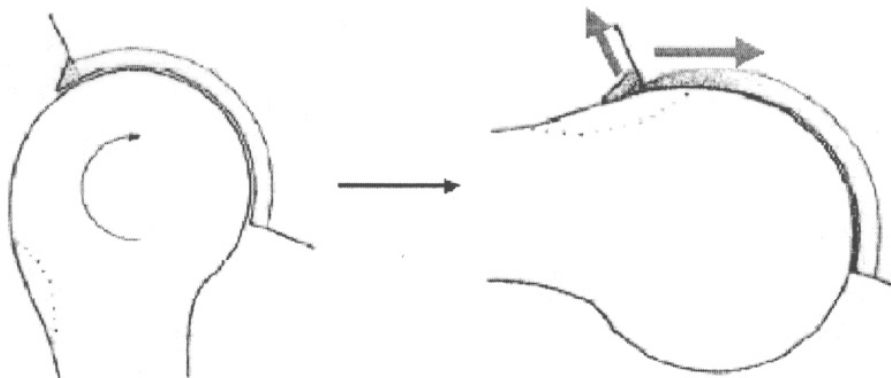
The mechanism of FAI was only described as recently as 2005. It is important to understand that all hips will impinge in people showing no symptoms, but only at the extremes of movement.

The difference between a normal hip and one with FAI is that the hip impinges much earlier in a patient with FAI. This occurs because of subtle differences in the anatomy of the hip joint. Essentially this difference is a surplus of bone, either on the edge of the acetabulum or on the femoral head-neck junction or both. If the acetabulum is tilted backwards (retroverted), the same effect occurs. The diagrams below illustrate this mechanism.

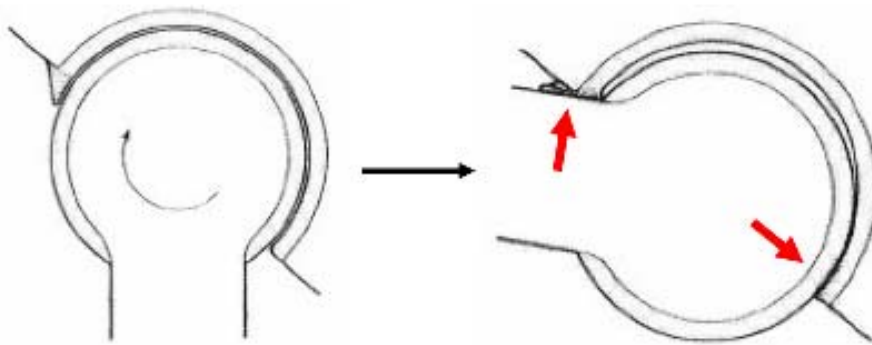
*Below: Normal hip joint, viewed from the side – no impingement at 90 degrees of hip flexion.*



*Below: Hip joint with impingement at 90 degrees of hip flexion, because of excess bone at the head-neck junction (shaded area). This type of impingement is termed '**Cam**' impingement. The arrows indicate the shear force applied to the acetabular cartilage (right arrow) and the displacing force applied to the acetabular labrum (left arrow).*



*Below: Hip joint with impingement at 90 degrees of hip flexion, because of excess bone in the anterior rim of the acetabulum. This type of impingement is termed 'Pincer' impingement. This results in direct damage to the labrum (left arrow) and the femoral head is levered backwards, damaging the cartilage at the back of the joint (right arrow).*



### Why does FAI cause pain?

As can be seen from the diagrams, FAI results in damage to the cartilage (shiny shock-absorbing layer) of the hip joint, as well as to the acetabular labrum (gristly bumper around the edge of the socket that helps to seal the joint). The labrum has lots of nerve endings so damage to it is painful. Cartilage does not contain nerves but it is likely that the increased force applied to the bone beneath the cartilage, which does contain nerves, causes the pain.

### Why is FAI important?

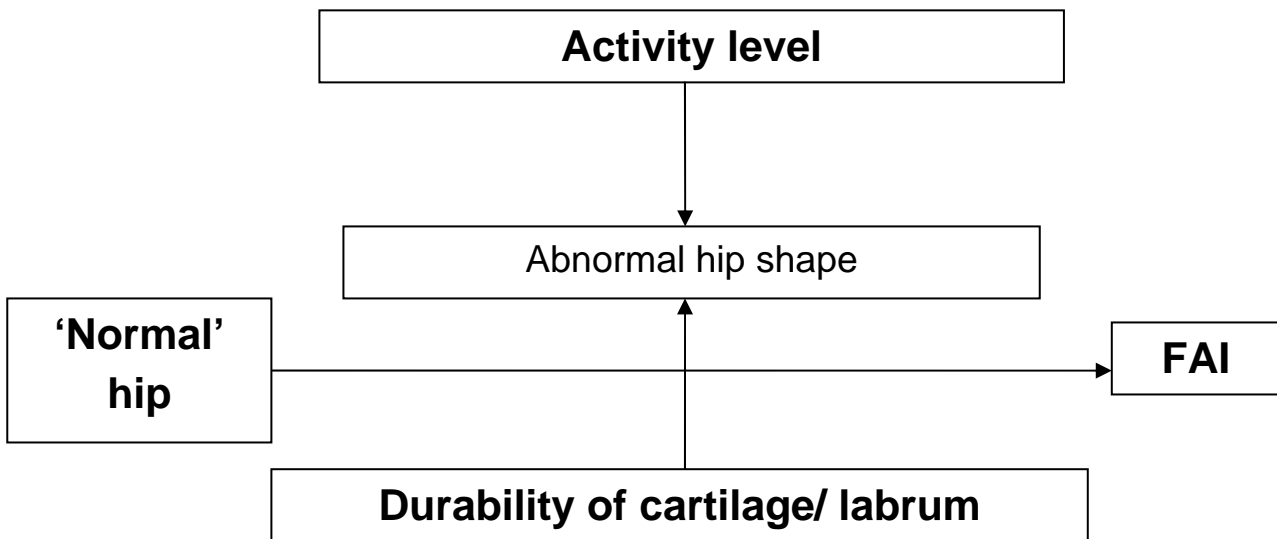
FAI is important for two reasons. First, it is a common cause of groin pain in young adults. Because FAI has only recently been understood, in the past such patients may have been misdiagnosed as having other conditions such as a muscle strain (groin strain), hernia, or inflammatory joint disease.

The second reason is that many surgeons believe that if untreated, FAI may result in hip arthritis, which may ultimately require a hip replacement. It is however important to understand that there are no studies yet that confirm that treatment of FAI prevents progressive wearing out of the joint and arthritis.

### What causes FAI?

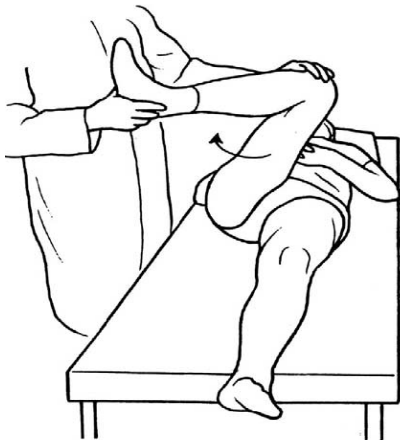
Some patients have a previous history of hip problems (such as injury or childhood hip conditions) and develop FAI as a secondary consequence. For the vast majority of patients however, there is no obvious reason why FAI occurs.

There are likely to be a number of factors (as shown in the following diagram) that determine whether symptoms occur. The primary problem is the subtle deformity in the joint shape, but this may or may not cause problems depending on the activity level of the patient and how easily their cartilage and labrum are damaged. Recent research from Oxford has shown a strong genetic predisposition to the condition.



### How is FAI investigated?

Initial consultation with your surgeon will focus on establishing if the pain is likely to be coming from the hip joint, and to rule out other sources and identify any factors making you prone to FAI. You will then be examined and a number of provocative manoeuvres will be performed (such as the impingement test shown below), to demonstrate the impingement.



Following the clinical assessment, x-rays of the hip will be taken to look for signs of arthritis, any other cause of hip pain, and the subtle bony deformities that are associated with FAI. It is likely that an MRI scan of your hip will also be done, to look in detail to see if the labrum is torn or if there is any sign of damage to the cartilage. Sometimes a CT scan will be arranged to look at the bony anatomy in more detail. It may be that the radiologist is asked to inject local anaesthetic into the hip, to help determine if your pain is coming from within the joint.

### How is FAI treated?

There are a number of treatments available, some are non – surgical, others surgical.

- 1) Nothing / Analgesia. Anti-inflammatories can be taken just before you perform an activity that brings on your hip pain so that it reduces pain and inflammation.
- 2) Activity modification. This involves avoiding activities that cause your symptoms and may involve avoiding particular sporting activity or changing your daily routine.
- 3) Physiotherapy. This can help to strengthen muscles around the joint and improve the range of motion

4) Injection. This accomplishes two things; if the pain is a result of FAI and originating from the hip joint it can provide pain relief. If successful it also rules out pain originating from the back, or any other potential source around the hip area.

5) Arthroscopy. Discussed below.

6) Arthroplasty. This refers to joint replacement and can take the form of re-surfacing arthroplasty or total hip replacement. Arthroplasty is carried out when the articular cartilage surface is significantly worn out.

Patients who wish to continue their activities may be advised to consider surgery. There are two main principles in the surgical management of FAI:

- 1) Deal with the damage caused to the acetabular cartilage and labrum.
- 2) Address the underlying bony deformity that caused the impingement in the first place.

Surgery may be performed via an open procedure, or via a keyhole (arthroscopic) technique. FAI is now the most common reason for a hip arthroscopy. Currently there is no evidence as to whether or not open or arthroscopic surgery is best. Our preferred approach is arthroscopic because we believe that recovery is quicker and there is less scarring that may compromise further procedures in the future.

### Dealing with the damaged acetabular cartilage and labrum

It is important to ensure that all unstable areas of cartilage are repaired or removed to prevent further damage.

Occasionally, simple debridement (removal) of the damaged tissue is all that is necessary to improve mechanical symptoms. Unfortunately, this tissue is not capable of healing itself. Often, it is necessary to repair the labrum if it is torn or detached. This is done using stitches that anchor into the bone of the acetabulum. If the articular cartilage has been worn away by the impingement, microfracture of the exposed bone (whereby the surface is punctured using a small pick) may encourage new cartilage to form. However, the long-term results of this procedure are not yet known.

### Treating the underlying bony deformity

Excess bone on the rim of the acetabulum and femoral head may be removed using a burr (a special type of drill). The aim is to remove enough bone so that there is no longer any impingement within a normal range of movement. This is confirmed with the camera and X-ray equipment, and by performing an impingement test.

The removal of bone from the femoral head-neck junction is called a 'femoral-osteochondroplasty', and from the acetabular rim a 'rim-trim'.

### What is the post operative rehabilitation?

This will depend upon the surgical procedure performed. Most patients are able to go home the day after surgery. Patients who have a microfracture will usually be asked to touch-weight bear for three to four weeks after surgery. Your rehabilitation will be carefully supervised by your physiotherapist. It is important to keep the joint mobile to prevent post-operative scar formation. Hydrotherapy (pool) may be used from the third post-operative week if your physiotherapist feels this is necessary.

(Please see the hip arthroscopy patient information leaflet for further information.)

### Does treatment of FAI improve symptoms?

The published evidence indicates that surgical treatment of FAI improves symptoms in the short-term. There is no evidence to indicate the best methods of treatment as yet.

The success of surgery will largely depend upon the degree of pre-existing damage to the cartilage and labrum.

Patients with areas of full-thickness cartilage loss will likely develop progressive arthritis in spite of surgery, although they may gain improvement in their range of motion in the short-term. There is no evidence as to whether treatment of FAI slows or prevents the progression of arthritis currently.

### What are the complications of FAI surgery?

The complications are the same as for a normal hip arthroscopy. In addition, femoral osteochondroplasty may theoretically weaken the bone leading to a risk of fracture; however, in practice this is extremely rare. The main risk is that the procedure does not improve the patient's symptoms significantly, or that they deteriorate after initial benefit.

(Please see the hip arthroscopy patient information leaflet for further information.)

### Research into FAI

Research is an essential part of surgical practice. FAI is a recently recognised phenomenon with many questions unanswered. It is therefore an area of intense research activity.

Furthermore, recent NICE guidance has recommended that hip arthroscopy should only be performed by surgeons who are collecting research data. Your surgeon will automatically collect pre- and post-operative scores to assess the outcome of your treatment. Please do not be alarmed if you are contacted 'out of the blue' regarding further research. All such studies go through a rigorous approval process and you will only be contacted with the prior consent of your surgeon who will have discussed this with you.

Participation is entirely voluntary and your care will not be influenced either way.

### Useful numbers and contacts

Hunter Ward (female):	0118 322 7536
Lister Ward (male):	0118 322 7538
RBH Outpatient Physiotherapy:	0118 322 7811
Wokingham Physiotherapy:	0118 949 5109
West Berkshire Physiotherapy:	0163 527 3362
Mr Andrade's secretary	0118 322 6851
Mr Pollard's secretary	0118 322 8191

For more information about the Trust visit our website: [www.royalberkshire.nhs.uk](http://www.royalberkshire.nhs.uk)

This document can be made available in other languages and formats upon request.

All information reproduced from Reading Orthopaedic Centre with permission of Mr Tony Andrade.

ORTH-P\_849

Reviewed: October 2014 by Debbie Burden (Orthopaedic Physiotherapy Specialist),

Tony Andrade (Consultant Orthopaedic Surgeon), Tom Pollard (Consultant Orthopaedic Surgeon).

Review due: October 2016